

# A histomorphometric and removal torque analysis of c.p. titanium implants inserted in reamed bone beds with and without acrylic cement

P. MORBERG, T. ALBREKTSSON

*Biomaterials Group, Department of Handicap Research, University of Gothenburg, Brunngatan 2, S-413 12 Gothenburg, Sweden*

The marrow cavity was reamed in both tibiae of six rabbits. In one of the tibiae curing bone cement was inserted. Two titanium implants were inserted in the proximal metaphysis of each tibia. The removal torque was recorded after 7, 14, 20, 27, 34 and 42 weeks. After each torque test the implants were rotated back until an insertion torque of 20 N cm was arrived at. The subsequent removal torque increased for each measurement in the two groups and levelled off in the range 60–80 N cm after 20 weeks in the reamed tibia and in the range 40–50 N cm after 34 weeks in the bone cement tibia. Histomorphometry at 50 weeks after cement insertion revealed a significantly higher percentage of direct bone-to-implant contact for the implants in the non-cemented side, 83.6% versus 71.9% for the cemented tibia. There was also a higher percentage of bone in the summed area inside the thread and in an image mirror area outside the thread in the non-cemented tibia, compared to the cemented side, 93.6 and 89.6% respectively.

## 1. Introduction

Major arthroplasties in the lower extremity are generally used in combination with acrylic cements [1]. However, cement-free implants have been prescribed in many cases as well, particularly for young individuals with an expected more extensive loading of the foreign materials. Neither technique has been without pitfalls: cemented arthroplasties do give rise to negative tissue reactions, and failures in the tissue-to-cement or metal-to-cement interface have not been uncommon with increasing time [1, 2]. Cement-free arthroplasties, on the other hand, have in many cases caused clinical problems resulting in an uncertainty if these devices in their present design really are advantageous compared to the cemented reconstructions [3]. At the insertion of cemented as well as non-cemented arthroplasties the bone marrow cavity is reamed. In the cemented case, curing methylmethacrylate is then added to the marrow. For both implant types, it is advocated [1, 4–6] that the outcome of the clinical procedure, at least in part, depends on the bone quality and subsequent healing capacity of the anchoring bone tissue. In the present investigation we have used a transcortically placed implant to test whether reaming in combination with bone cement will significantly impair the healing capacity or not. By interrupting the incorporation of our transcortical screw implants at varying time intervals, the healing capacity of bone where only reaming of the marrow cavity was performed could be compared with the

healing capacity of a bone bed that had also been filled out with acrylic cement. In this way short-term as well as long-term effects of the healing capacity in the two types of bone bed could be analysed.

## 2. Experimental procedure

### 2.1. Animals and anaesthesia

Six adult New Zealand White rabbits, between 9 and 12 months of age, were used in the study. Anaesthesia was induced with i.m. injections of Hypnorm® (Mekos) at a dose of 0.25 ml per kg body weight and i.p. injections of Valium® (Roche) at 0.5 mg per kg body weight. Additional doses of Hypnorm® at 0.1 ml per kg body weight were used to maintain anaesthesia, if necessary.

### 2.2. Implants and surgical technique

The screw-shaped implants were manufactured of commercially pure (c.p.) titanium. The diameter of the threads was 3.7 mm and the top of the implants was square-shaped to fit a specially constructed connector. Both tibiae of the animals were, after sectioning of the soft tissues, reamed by drilling two holes, one in the proximal part of the bone and one at the distal end of the tibia. Through repeated high-pressure injections of saline into the proximal hole the marrow contents were removed through the distal hole. 5 mm distal to the proximal hole, another hole was drilled in the

proximal tibial metaphysis. In one tibia, methylmethacrylate in form of low-viscosity bone cement (Zimmer) was then injected with a 2 ml syringe press-fitted into the most proximal hole in the tibial metaphysis. When the bone cement bulged out through the two other holes in the tibia, manual pressure prevented further leakage. A new 2 ml syringe with bone cement was then inserted in the proximal hole and further injection of cement was performed with maximal manual pressure that was maintained until polymerization of the bone cement ceased. The hole through the cortex was then enlarged and a continuous hole was drilled into the bone cement. The diameter of the hole in the bone cement was enlarged by milling with a fine drill without simultaneously drilling the cortex of the bone. In this way the implants were, after threading the cortex and subsequent insertion, only in contact with the cortex and not with the surrounding bone cement. Threading was performed with three revolutions per minute. All surgical procedures were performed with very gentle surgical technique and careful cooling to ensure minimal tissue damage. The implants were screwed home to a level where there was only one thread visible over the cortical plane. After surgery the animals were allowed full weight-bearing.

### 2.3. Torque measurements

After 7 weeks the soft tissues were again sectioned to expose the tops of the screws. All soft tissues growing on and around the screws were carefully removed. After connecting the manometer the screws were removed during recordings with a Tochnichi 15 BTG-N torque instrument. The screws were then reinserted with an insertion torque of 20 N cm and the soft tissues were sutured. After 14, 20, 27, 34 and 42 weeks the procedures were repeated in the same manner. The animals were sacrificed after 50 weeks and the implants were then cut out for histological preparations.

### 2.4. Histological preparations

After sacrifice of the animals the implants were cut out *en bloc* with the surrounding bone tissues. The specimens were dehydrated and embedded in methylmethacrylate plastic. Using the procedure described by Donath and Breuner [7] sections were made through the implants and the surrounding undecalcified bone. After grinding the sections to a thickness of approximately 10  $\mu\text{m}$  they were stained in 1% toluidine blue in a 1% borax solution mixed in proportions 4 to 1 with 1% pyronin-G solution. The interfacial tissue reaction was studied under a light microscope. The amount of bone apposed to the surface of the metal was calculated for the entire screw using a computer-based morphometric assessment. As the cemented side contained a spacer in the medullary cavity, only the best three consecutive threads on each side of the implant were used for the evaluations. The percentages of cortical bone inside the thread and in a mirror-image area on the outside were calculated for the best two consecutive threads on each side of the implant. As the area calculations were performed both

inside and in a mirror-image area outside the thread it was usually not possible to find more than two threads with cortical bone in both these areas. One section from all implants were examined, with a total of 24 sections evaluated.

### 2.5. Statistics

The results were statistically evaluated using the Wilcoxon signed rank test for all observations except for removal torque after 42 weeks (as it contained less than six observations) where Student's *t*-test was used.

## 3. Results

After 7 weeks all animals were healthy and there were no signs of local infections. All implants in the tibias that were reamed and filled with bone cement were loose and no removal resistance was registered. In the other tibias which were only reamed previous to implant insertion, all implants were stable and the average torque resistance was 34 N cm (12–80 N cm). At 14 weeks four of the twelve implants in the bone-cement tibias were still loose. In three cases, two after week 14 (animals 1 and 6) and one after week 20 (animal 3) there was hard tissue growing up on the implants which made it impossible to connect the manometer. This bone tissue was removed and the values were excluded. The mean torques for the PMMA and reaming groups, when overgrown implants were excluded, were 16 and 58 N cm, respectively ( $p = 0.014$ ).

The number of loose implants in the PMMA group had decreased to two after 20 weeks and the mean removal torque increased in both groups to 23 N cm in the PMMA group and to 76 N cm in the reaming group ( $p = 0.014$ ). The last loose implant was registered in the 27-week PMMA group which had a mean removal torque of 39 N cm, while the mean removal torque was 82 N cm in the reaming group ( $p = 0.014$ ). After 34 weeks the mean removal torque was 48 N cm in the PMMA group and 80 N cm in the reaming group ( $p = 0.014$ ). One animal died during anaesthesia before torque measurements at week 42. The implants were then cut out for histological preparations and the torque values are therefore missing for animal 3 after week 42. The mean removal torque in the PMMA group was 48 N cm and it was 65 N cm in the reaming group ( $p = 0.019$ ). The removal torques for the PMMA implant groups were at all torque registrations lower than for the reaming groups ( $p = 0.014$ ). The removal torque registrations are summarized in Table I and the average removal torques are plotted in Fig. 3. Histologic evaluation of proximally placed implants in the cemented group demonstrated significantly less bone compared to the reamed group; 66.2% versus 78.8% ( $p = 0.014$ ). A similar pattern with significantly less bone in the cemented side compared to the reamed side was present for the distal implant: 77.6% versus 88.4% ( $p = 0.014$ ). The bone implant contact is listed in Table II.

The calculations of percentage of bone inside the thread and in a mirror-image area outside the thread

TABLE I Removal torque ratios for two screw implants, inserted in each rabbit tibia (PMMA = tibia containing methylmethacrylate bone cement, Ream = reamed only)

Animal no.	Screw no.	Torque ratio (PMMA/Ream)					
		Week 7	Week 14	Week 20	Week 27	Week 34	Week 42
1	1	0/80	40/-	28/38	32/52	42/100	38/41
	2	0/60	12/50	24/72	36/60	48/80	54/62
2	1	0/26	0/54	42/100	60/140	59/160	54/57
	2	0/23	15/63	35/140	60/112	70/69	56/66
3	1	0/20	20/30	0/54	32/100	44/48	-/-
	2	0/30	42/60	-/60	46/65	42/55	-/-
4	1	0/12	0/42	10/46	32/55	32/52	40/53
	2	0/18	0/70	10/64	40/75	46/80	43/88
5	1	0/18	0/64	0/100	0/92	34/72	34/63
	2	0/28	57/70	67/78	47/52	44/53	41/55
6	1	0/42	10/60	28/72	38/86	50/100	56/72
	2	0/55	-/65	30/84	42/92	73/96	65/104

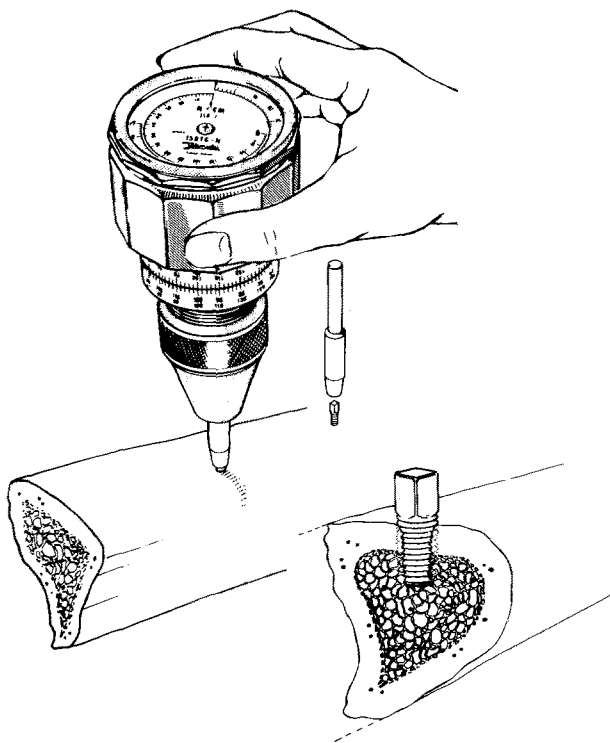


Figure 1 Removal torque screw *in situ*. The square-shaped top fits to a specially constructed connector. A Tochichi 15 BTG-N torque gauge instrument was used to unscrew the implants.

(Fig. 2) demonstrated significantly less bone inside compared to the outside in the two groups. The cemented tibia revealed a ratio of 87.5% to 91.6% ( $p = 0.014$ ), whereas for the reamed tibias this ratio was 90.2% to 96.7% ( $p = 0.014$ ). In this study the mirror-image measurements were matched so that we were also able to compare the bone surface areas between the reamed and the cemented group. Here there was a significant difference in that the summed inside and outside measurements on the reamed side demonstrated a bone percentage of 89.6% on the cemented side compared to 93.4% on the reamed side ( $p = 0.023$ ). The bone areas inside the thread and outside in a mirror-image area are summarized in Table III.

TABLE II Bone-implant contact for screw-shaped implants after 50 weeks of insertion (No. 3 42 weeks); each rabbit had two implants inserted in each tibia (PMMA = tibia containing methylmethacrylate bone cement, Ream = reamed only)

Animal no.	Contact area (%)			
	Proximal		Distal	
	PMMA	Ream	PMMA	Ream
1	43.75	67.98	76.97	95.93
2	80.50	86.13	90.42	95.41
3	71.53	90.48	75.98	90.90
4	59.97	67.26	81.39	86.23
5	61.33	72.33	75.50	77.78
6	80.19	81.74	72.82	84.21

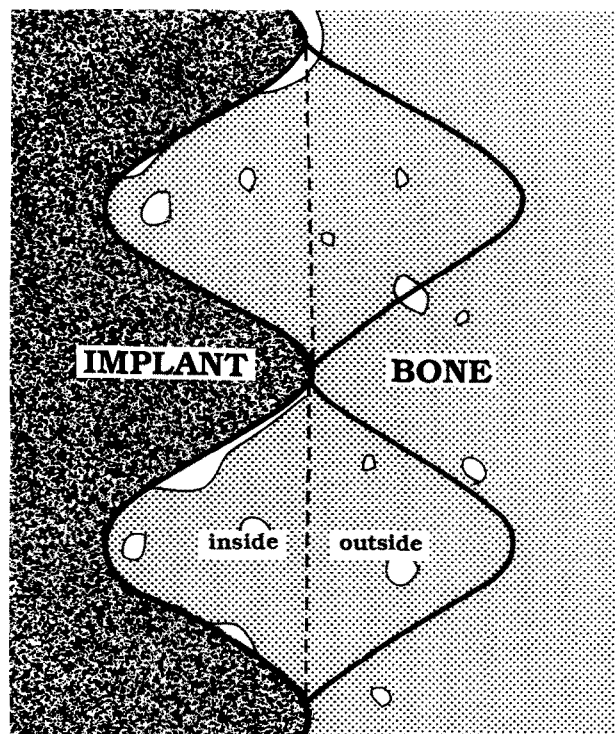


Figure 2 The percentage of bone was calculated in matched areas inside the thread and on the outside, in a mirror-image area.

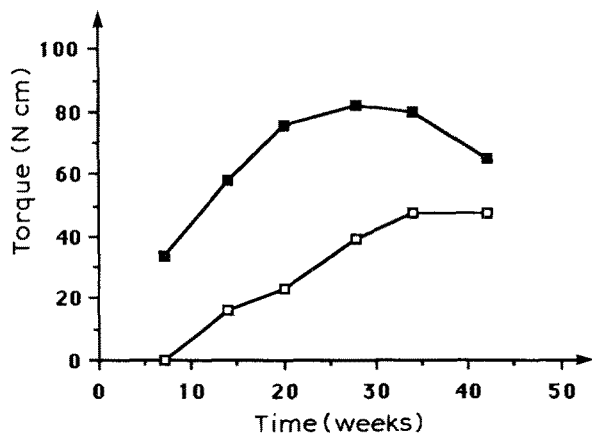


Figure 3 Average removal torque for titanium implants, inserted in the rabbit tibia, at 7, 14, 20, 27, 34 and 42 weeks after insertion: (□) reamed and cemented tibias, (■) reamed tibias.

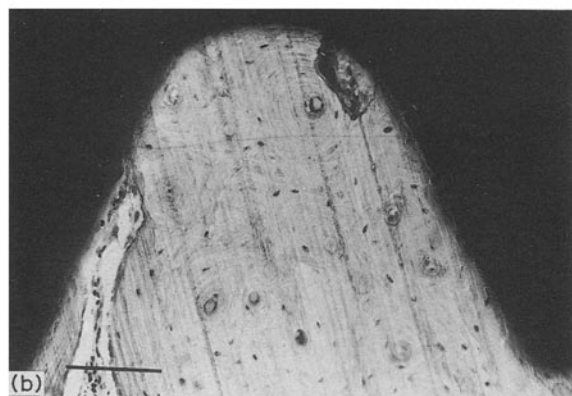
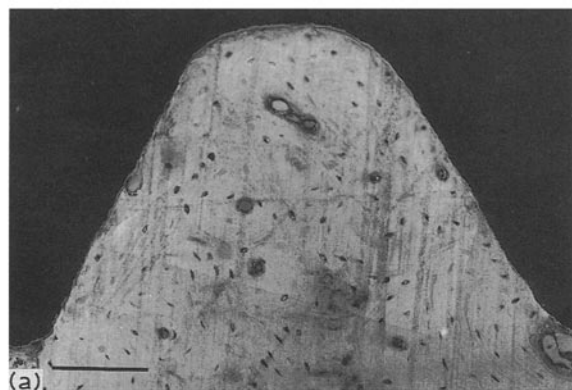


Figure 4 (a) Direct bone-to-titanium implant contact of a screw inserted for 50 weeks in a reamed tibia. The average bone-implant contact was calculated using a computer-based morphometric assessment on 10  $\mu$ m thick ground sections. (b) A titanium screw inserted for 50 weeks in a reamed and cemented tibia. In this tibia bone formation was significantly impaired. Bar = 100  $\mu$ m.

#### 4. Discussion

This work demonstrated that the implant incorporation capacity was impaired after insertion of methylmethacrylate. This was not only an acute effect due to monomer toxicity, heat and surgical trauma. Significantly lower removal torques were repeatedly registered up to 42 weeks for implants inserted in tibias filled with bone cement compared to implants inserted in reamed tibias. After 50 weeks there was still a lower percentage of bone-to-implant contact and less cor-

TABLE III Percentage of bone area calculated in two matched areas inside the thread and on the outside in a mirror-image area (Fig. 2) (Ream = reamed only, PMMA = tibia containing cement)

Animal no.	Tibia	Bone area (%)			
		Ream		PMMA	
		Inside	Outside	Inside	Outside
1	Prox.	89.5	95.0	91.0	93.2
	Dist.	91.3	99.6	80.0	78.8
	Mean	90.4	97.3	85.5	86.0
2	Prox.	97.5	99.1	79.0	94.6
	Dist.	93.7	96.0	93.6	97.1
	Mean	95.6	97.6	86.3	95.8
3	Prox.	94.7	93.1	89.2	94.1
	Dist.	95.3	99.2	92.0	97.1
	Mean	95.0	96.2	90.6	95.6
4	Prox.	80.4	98.0	89.5	94.3
	Dist.	85.6	98.8	90.0	89.5
	Mean	83.0	98.4	89.8	91.9
5	Prox.	82.3	91.0	84.0	85.6
	Dist.	92.9	95.9	88.4	88.4
	Mean	87.6	93.4	86.2	87.0
6	Prox.	87.6	96.2	85.4	94.3
	Dist.	90.7	98.6	87.9	91.3
	Mean	89.2	97.4	86.6	92.8
	Mean prox.	88.7	95.4	86.4	92.7
	Mean dist.	91.6	98.0	88.6	90.4
	Mean all	90.2	96.7	87.5	91.6

tical bone close to the implants of the cemented side compared to the reamed one.

This model experiment was an attempt to imitate the clinical insertion of bone cement, even though the test screw implant was transcortically inserted and the reaming was only performed with a syringe. Reaming with saline is less traumatizing compared to surgical reaming, which removes not only medullary contents but also cancellous bone and parts of the endosteum. The rabbit tibia in the region where the implants were inserted consists almost totally of cortical bone and the marrow contents were therefore easily removed without any additional instruments. This reaming procedure will remove the marrow contents but the surgical trauma is negligible.

There are several potential drawbacks with bone cement that may contribute to the adverse reactions seen in the cemented tibia. The acute effects demonstrated by the loose implants in the seven-week removal test were probably the result of negative factors related to the curing of acrylic cement, such as impaired circulation, high pressure, and heat and monomer toxicity. However, it seems unlikely that the acute effects of bone cement will cause such a long-term injury to the bone repair as that observed in this paper. The acute effects on the bone circulation and the reaming pressure were identical on the two sides and are therefore unlikely as an explanation for our long-term observed differences. The monomer trauma is seen mainly in the acute phase after cement introduction and previous investigators have failed to demonstrate long-term adverse effects of the leaking

monomer [8, 9]. The heat elicited from curing cement has been demonstrated to result in temperatures of the order of 70 °C [8]. This heat impact may surely cause an acute bone injury as the critical time/temperature of 47 °C for 1 min was exceeded [10]. However, it seems unlikely that a permanent bone injury is caused by the level of exothermic reaction when cement is curing [11].

Thus, ignoring the acute tissue effects, we would have two possible explanations for the long-term impaired bone repair capacity of the cemented tibia compared to the one that was only reamed: a long-term cell disturbance due to toxic components such as DmPT and/or an effect of the fact that the marrow cavity on the cemented side was filled by a spacer, which could be assumed to potentially disturb the restoration of the normal circulatory pattern. We decided against using a spacer control in our experiment as such a control must be totally inert as well as being of a very similar elastic modulus to the polymerized bone cement to allow for any comparisons. These demands exclude metallic spacers. A potential spacer such as hardening silicon was regarded unsuitable because of leakage of acetic acid. Polymers are either not adequately inert or would be difficult to introduce into the marrow cavity without substantial surgical trauma [12, 13]. Beeswax, another candidate for a spacer, has been demonstrated to induce a chronic inflammation with a marked foreign-body reaction [14].

However, in spite of being filled out by acrylic, the cemented side in our experiment was not without regenerating vessels in the marrow cavity. The bone cement shrinks at the end of polymerization and there is always a small gap between the bone and the methylmethacrylate. This thin gap between bone and cement is sufficient for tissue regeneration [15] but it may be a poor substitute for a complete regeneration of the marrow circulation. Therefore, the endosteal regeneration and subsequent healing capacity of the cortex may potentially be permanently impaired by the introduced bone cement even if this is totally inert. On the other hand, the medullary implant will stimulate periosteal bone apposition [16] which may increase the incorporation of the superior threads of the implants. In addition, as mentioned previously bone cement even in its cured form is not inert and leakage of toxic substances may impair the healing capacity of the bone [17–19].

However, irrespective of the precise mechanism, it may be concluded from the results of this experiment that introduced bone cement caused a long-term disturbance of the cortical bone regenerating potential.

New research is motivated to identify possibly improved types of bone cement without long-term side effects, or to find improved types of cement-free arthroplasties compared to the currently used designs that in many cases have questionable clinical outcome [1].

## Acknowledgements

This study has been supported by grants from Greta and Einar Askers Foundation, King Gustav V Jubilee Foundation, Swedish Medical Society, Gothenburg Medical Society, Swedish Society for Medical Research and the Medical Research Council (MFR).

## References

1. L. AHNVELDT, P. HERBERTS, H. MALCHAU and G. B. J. ANDERSSON, *Acta Orthop. Scand. Suppl.* 238, **61** (1990) 1.
2. R. HUISKES, in *Proceedings of Workshop on the Bone-Implant Interface*, edited by J. L. Lewis and J. O. Galante (American Academy of Orthopaedic Surgeons, Park Ridge, Illinois, 1983).
3. T. ALBREKTSSON, in "Bone: A Treatise", Vol. 7, edited by B. K. Hall (Telford Press, Caldwell, N.J., in press).
4. L. C. JONES and D. S. HUNGERFORD, *Clin. Orthop.* **225** (1987) 192.
5. R. JUDET, M. SIGUIER, B. BRUMPT and T. JUDET, *ibid.* **137** (1978) 67.
6. J. de WAAL MALEFIJT, thesis, University of Nijmegen, The Netherlands (1988).
7. K. DONATH and G. A. BREUNER, *J. Oral Pathol.* **11** (1982) 318.
8. L. LINDER, in "Biocompatibility of Orthopaedic Implants", Vol. 2, edited by D. F. Williams (CRC Press, Boca Raton, 1982).
9. L. LINDER and M. ROMANUS, *Clin Orthop.* **115** (1976) 303.
10. L. E. ERIKSSON and T. ALBREKTSSON, *J. Prosth. Dent.* **50** (1983) 101.
11. A. ERIKSSON, thesis, University of Gothenburg (1984)
12. T. ALBREKTSSON and F. BUCH, *Arch. Orthop. Traum. Surg.* in press.
13. P. THOMSEN, L. M. BJURSTEN and L. E. ERIKSSON, *Scand. J. Plast. Reconstr. Surg.* **20** (1986) 173.
14. B. SUDMANN, O.-H. ANFINSEN, M. RAITL, G. BANG and E. SUDMANN, *Acta Orthop. Scand. Suppl.* 237, **61** (1990) 63.
15. K. DRAENERT, in "Implant Bone Interface", edited by J. Older (Springer, London) p. 25.
16. G. SUND and J. ROSENQUIST, *Acta Orthop. Scand.* **55** (1984) 83.
17. T. ALBREKTSSON, *Arch. Orthop. Traum. Surg.* **102** (1984) 141.
18. F. LINTNER, *Acta Chir. Austr.* **48** (suppl.) (1983) 3.
19. P. MORBERG and T. ALBREKTSSON, submitted.

*Received 21 March  
and accepted 24 April 1991*